

# Bilateral hydrosalpinges, what to do :Salpingectomy or salpingoplasty? Result of a 480 cases continuous series



Antoine Watrelot<sup>a,\*</sup>, Jing Guan<sup>b</sup>

<sup>a</sup> Centre lyonnais de l'endometriose, Hôpital Natercia 22 avenue Rockefeller, 69008, Lyon, France

<sup>b</sup> Peking University People's Hospital, 11# Xizhimen Street, Beijing, 100044, China

## ARTICLE INFO

### Keywords:

Tubal infertility  
Hydrosalpinx  
Salpingoneostomy  
In vitro fertilization

## ABSTRACT

**Background:** Hydrosalpinx is the most common lesion of the distal part of the tube. Hydrosalpinx is well known to have deleterious effect on fertility.

**Methods:** Two options are doable in case of hydrosalpinx: radical treatment(salpingectomy) or conservative treatment (salpingoneostomy).

**Results:** This work demonstrates that in experienced hands and with an acute selection, salpingoneostomy gives results comparable to those obtained after IVF.

The cuff salpingoneostomy technique is much better than racket form salpingoneostomy and should be preferred whenever it is possible.

**Conclusions:** Conservative treatment should be discussed in infertile patients having hydrosalpinx after a careful selection.

## 1. Introduction

There is now evidence that hydrosalpinx has a deleterious effect on fertility even if the mechanisms are still not completely clear. As suggested by its name, hydrosalpinx occurs when the fallopian tube is blocked and is full of clear fluid, often as the result of infection or endometriosis. A hematosalpinx occurs when the tube is full of blood. When both tubes are obliterated, infertility is obvious. When hydrosalpinx is unilateral, in theory pregnancy may be obtained but since the works of Strandell, it is now well known that the deleterious effect on hydrosalpinx on fertility is important.<sup>1</sup> If in-vitro fertilization (IVF) is performed when hydrosalpinx is present the pregnancy rate decreases by a margin of almost 50%.

The mechanism which reduces the pregnancy rate is not totally elucidated but one possibility is that the liquid inside the tube has a toxic effect on the embryo, and that this liquid may come in the uterus around the time of ovulation thus, being embryo-toxic.<sup>1,2</sup>

In case of unilateral hydrosalpinx, treatment of hydrosalpinx is

generally the first step of an IVF program.<sup>3</sup> In case of bilateral hydrosalpinx, if a conservative therapeutic option is chosen, it preserves the possibility to obtain a spontaneous pregnancy. Therefore, in an infertile patient, it is important to treat hydrosalpinges even when unilateral.

In case of hydrosalpinx two therapeutic options are available radical or conservative, i.e., salpingectomy or salpingoplasty. In fact, in most centers only the radical option (salpingectomy) is usually offered to patients, and it seems that tuboplasty is more and more a lost technique. Considering the expected results of tuboplasty, it is interesting to discuss the existing options available in case of hydrosalpinx. Every option has its advantages and should be balanced with the result of In vitro fertilization (IVF) which is the only alternative once salpingectomy has been performed. The objective of this paper is to compare the various options in order to give the patients the best chances to become pregnant.

## 2. Material and method

Between 1988 and 2018, we have operated conservatively

\* Corresponding author.

E-mail address: [watrelot@watrelot.org](mailto:watrelot@watrelot.org) (A. Watrelot).



<https://doi.org/10.1016/j.gocm.2020.10.003>

Available online 8 December 2020

2667-1646/© 2020 Chinese Journal of Clinical Obstetrics and Gynaecology Press. Publishing services by Elsevier B.V. on behalf of KeAi Communications Co. Ltd. This

is an open access article under the CC BY-NC-ND license (<http://creativecommons.org/licenses/by-nc-nd/4.0/>).

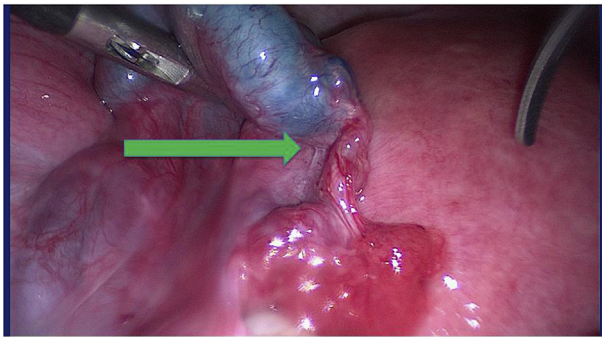


Fig. 1. Hydrosalpinx with still Cumbria without connection with ampulla (green arrow).

(salpingoplasty) on 480 patients with bilateral hydrosalpinx. For the series are reviewed, it is exempted by local ethic committee. Written consent were obtained from all the patients for operation and patient consented for publication. In order to benefit from the reconstructive surgery, patients had to meet a number of criteriae such as tubal quality and acceptance, after being informed of the failure rate and the risk of recurrence or the occurrence of an ectopic pregnancy. It was therefore important to clearly define what is hydrosalpinx, what are the criteria for reconstructive surgery and what were the possible techniques.

2.1. The hydrosalpinx

It is of paramount importance to define accurately the tubal lesions. There is sometimes confusion between phimosis and hydrosalpinx. In phimosis there is still a certain degree of patency, whereas in hydrosalpinx there are no patency at all. This makes a very large difference in prognosis when operated since the tubal mucosa is usually healthy in phimosis but frequently altered in hydrosalpinx. However, in some cases there is what it looks like a normal fimbria, but when the dye test is performed it is very clear that the ampulla is totally blocked without any connection between the fimbria and the ampulla (Fig. 1).

2.2. Adhesions

Adhesions are frequent since hydro or hemato-salpinges are usually the result of PID or endometriosis where inflammation is important, thus creating adhesions. It is necessary to pay attention to the quality of adhesiolysis: it should be accurate, atraumatic and complete. Various tools may be used such as cold scissors, monopolar hook or Plasmajet®. None has proven to be superior to the others so everything is useable providing to be precise. In our series, we usually used cold scissors or monopolar hook and Plasmajet in case of hydrosalpinges associated with endometriosis. Considering the role of adhesions in the prognosis of salpingoneostomy we used the AFS adhesion score (Table 1) and did not operate conservatively in case of frozen pelvis (score equal to 16 or above).

2.3. The techniques of salpingoneostomy

The conservative operation is called salpingostomy or even better salpingoneostomy (since a “new” ostium is created). There are two kinds of salpingostomy: the terminal neostomy and the medio ampullary neostomy. In the latter case, a part of the distal ampulla (usually one or two centimeters) is removed. This technique, which was popular in the eighties, is abandoned today, since the results are not at all competitive with results obtained with IVF. So, in this paper salpingoneostomy refers to terminal salpingoneostomy exclusively.

There are two techniques of terminal salpingostomy: the cuff

Table 1  
The AFS adhesion scoring system.

Organ	Kind of adhesion	Surface		
		1/3	2/3	3/3
Ovary	Filmy	1	2	4
	Dense	4	8	16
Tube	Filmy	1	2	4
	Dense	4	8	16

Stage 1:(minimal) score 1 to 6; Stage 2(mild):7 to 15, Stage 3 (severe):>15.

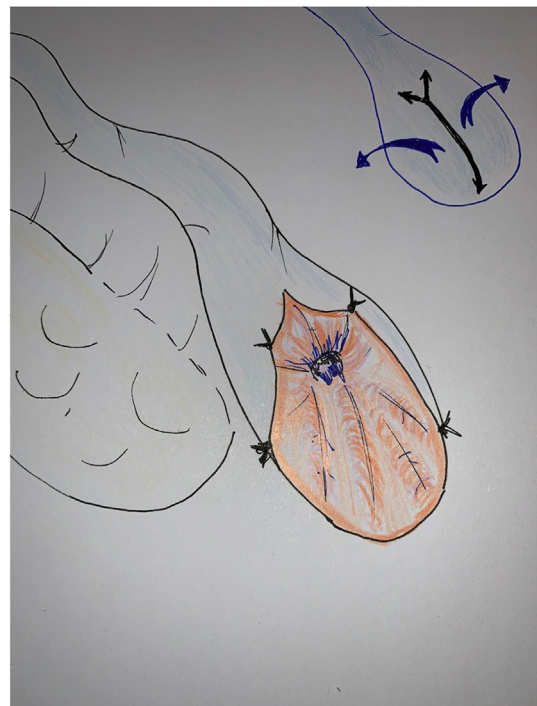


Fig. 2. Ratchet form salpingostomy.

salpingostomy (Fig. 3) and the ratchet form (Fig. 2). In our series, whenever it was possible, we practiced the cuff salpingostomy and the ratchet form otherwise. In fact, cuff salpingoneostomy is only possible when the tubal wall is thin and non sclerotic. In cases where only the ratchet is possible the tube is not in a good condition. That will be reflected by the results described below. All hydrosalpinx do not have the same prognosis. The key factors are the quality of tubal mucosa and the thickness of the tubal wall.

The tubal mucosa is probably the most important parameter allowing surgery to be conservative or not, as demonstrated by Brosens and Puttemans(4,5). They described a “tubal score” where stage 1 is normal, in stage 2 the mucosal folds are decreasing, in stage 3 there are additional focal intra ampullary adhesions, and in stage 4 and 5 folds are totally flattened or absent and ampulla is full of adhesions with the “honey comb” aspect (Table 2). When tubal mucosa is stage 3–5, the pregnancy rate after salpingostomy is very low, between 17% and 0% in stage 5, with a risk of ectopic pregnancy of more than 10%. Therefore, in these cases, salpingectomy is the only option prior to IVF.

The second parameter is the thickness of the tubal wall. In case of a sclerotic tubal wall, prognosis of conservative treatment is not good, even if the hydrosalpinx is quite small. In case of big hydrosalpinx, if the tubal wall is thin, the prognosis is fairly good. This is not well known, since many authors consider that “big” hydrosalpinges should be treated radically.<sup>6,7</sup> In our series, we only consider for reconstructive surgery

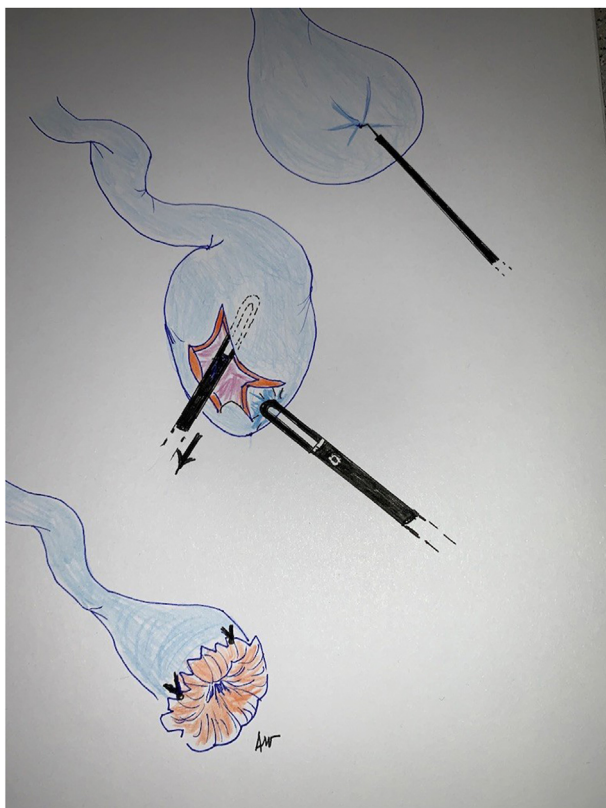

Fig. 3. Cuff salpingostomy.

Table 2

Tubal mucosal score.

Tubal score of Brodens
1 = normal folds
2 = distended folds
3 = Focal lesions (mucosal deposit, adhesions, polyp)
4 = extensive lesions
5 = dispartition of the folds
1&2 are normal aspects, 3,4, and 5 are pathological

patients with a mucosal score stage 1 or 2. In stages 3–5 we recommended salpingectomy followed by IVF.

We performed all salpingoplasty through laparoscopy using the technical requirements recommended by Gomel and Winston<sup>8,9</sup> in the eighties and used at that time through microsurgical laparotomy. Today, the prerequisites of tubal surgery such as magnification and gentleness are perfectly doable by laparoscopy. We applied strictly these principles in our series.

In case of hydrosalpinx, the conservative operation is called salpingostomy or even better salpingoneostomy, consisted first in finding the place of the old ostium to start the opening. Once that was done, stellar incisions following the fibrotic tissue were done by cutting or gently distracting the tissue with two atraumatic forceps. In case of a thin wall, we used the technique of cuff salpingoneostomy. When the tubal wall was a little thicker, only the racket form was doable. When eversion was performed, it was maintained with micro-sutures, usually 6 × 0 or 7 × 0 monofilament sutures. Three to four stitches were sufficient to maintain the obtained eversion. It was important to try to cover all the tubal serous area damaged by coagulation in order to prevent adhesion formation on those areas. At the end of the procedure, tubal patency was tested, through the cervix by injection of methylene blue, and copious pelvic irrigation was done. We routinely use 4% icodextrin (Adept®)<sup>10,11</sup> due to its antiadhesion properties demonstrated in several trials, and

Table 3

Results of salpingoneostomy according to the technique (Hydrosalpinx treated by laparoscopic surgery 1998–2018) n(%).

	N	Pregnant	Miscarriage	Ectopic
Racket salpingoneostomy	113	28(24.8)	14(12.3)	9(7.9)
Cuff salpingoneostomy	367	210(57.2)	38(10.3)	10(2.7)
Total	480	238(49.5)	52(10.8)	16(3.3)

300–500 cc was left in place at the end of the procedure.

### 3. Results

Between 1988 and 2018, 480 patients were operated by the same surgeon, AW. Age of patients were 24–40 with a median of 32.5. All patients had bilateral hydrosalpinges. Among them only 134 (27.9%) had a past history of genital infection but 274 (57%) had a positive chlamydia serology and 78 (16.25%) had evidence of endometriosis. So, in 128 patients (26.6%) no cause was found. Results are summarized in Table 3. Patients were lost to follow up 61 (12.7%) considered as failure.

A racket form salpingoneostomy was performed in 113 cases, with 28 patients (23.5%) who became pregnant. Of these, 14 patients had a miscarriage and 9 had an ectopic pregnancy. Just 5 patients had a live baby which leads to a take home baby rate of only 4.4%. In the 367 other cases (76.4%), a cuff salpingoneostomy was possible leading to 210 pregnancies (57.2%). Among them 38 (10.8%) had a miscarriage and 10 (3.9%) an ectopic pregnancy. The take home baby rate (162/367) was 44.1% (Table 3).

Considering the two techniques together, the overall pregnancy rate was 49.5% with 10.8% of miscarriages and 3.0% of ectopic pregnancy and a combined take home baby rate of 34.7%. Time to become pregnant was variable, with 20 (8.4%) patients becoming pregnant before 6 months, 54 (22.6%) between 6 and 12 months and 164 (68.9%) after 12 months. In case of recurrence (demonstrated by hystero-salpingography; HSG) or if no pregnancy occurred, no repeated procedures were done and IVF was proposed. No post-operative complications were observed.

### 4. Discussion

In case of hydrosalpinx, salpingectomy is generally offered to the patient prior to IVF. Advantages are quite evident: the treatment is definitive, pregnancy through IVF is roughly 40% per attempt and may be quickly obtained. On the other hand, salpingectomy, especially if bilateral, is often not well accepted by patients. The psychologic burden of such “mutilation” being too difficult to bear. Therefore, patients are quite demanding of a conservative option. Advantages of salpingoneostomy are the possibility of a natural conception, possibility to have more than one child, and the relatively low cost compared to IVF.<sup>12,13</sup> Disadvantages are the risk of recurrence, and the time to get pregnant usually between 6 and 12 months which is longer than with IVF. In our series most of our pregnancies were obtained after 12 months which is consistent with the “historic” series published by Winston in 1978. Considering the IVF result, salpingoneostomy is a valid option when the results in term of pregnancy is around 50%.<sup>14,15</sup>

Technically, salpingoneostomy is not considered as a very difficult procedure, however it has to be done in experienced hands as demonstrated by Linford<sup>3</sup> in 1990 showing that in a general hospital the pregnancy rate after salpingoplasty was only 5%, leading the authors to conclude that tubal surgery should be abandoned in favor of IVF. However, in experienced hands, results can be quite different<sup>17</sup> and a pregnancy rate similar to IVF may be expected if the technique is adequate. Today, laparoscopy is the approach of choice and, when performed according to the principles of microsurgery, gives results equivalent to those obtained by conventional microsurgery, but in a minimally invasive way.

At the technical level, our results show that the cuff salpingostomy gives results ten times superior to the racket technique. The discrepancy



between these two techniques underline once again the need for a very strict selection to obtain good results with tubal surgery. The main criteria of selection are the quality of tubal mucosa and the thickness of the tubal wall. It seems therefore logical to only practice the cuff technique, and propose IVF when it is not possible. Even though no randomized controlled trial (RCT) comparing IVF and salpingoneostomy exists, the results of cuff salpingoneostomy are quite competitive with IVF.

We did not use bipolar coagulation or CO2 laser to maintain the tubal eversion. This technique was seen as an elegant one with the “flower effect”, at a time when laparoscopic microsuturing was difficult. In fact, this approach could be deleterious. If thermal energy is applied at the base of the new ostium, it creates a sclerotic ring which may impair the tubal function. Nowadays, laparoscopic suturing is well mastered and the use of microsutures is required, with 6 × 0 or 7 × 0 monofilaments the material of choice.

Fallopian tubes are very fragile structures and any trauma will cause inflammation with the cascading events of sclerosis, and adhesions. Therefore, the quality of suturing, respect of the tube by not using teeth grasper, economical coagulation, and constant irrigation with ringer lactate or Adept are essential.

One last element must be taken into account: the human element. To decide to remove or conserve the tube is a decision which cannot be taken by the surgeon alone. The patient's choice is critical. The feeling of mutilation when tubes are taken out is very difficult to accept by infertile women. So, it is of utmost importance to discuss the different options with the patients after clear and frank information. In case of unilateral hydrosalpinx, patients usually agree to salpingectomy if needed. In case of bilateral hydrosalpinx the burden of bilateral salpingectomy is very difficult to bear. Therefore, in these cases, conservative treatment is often favored by the patients but the surgeon has to be very clear and explain that success is not taken for granted, due to the risks of recurrence. The patient may face a second laparoscopy for salpingectomy is salpingoneostomy has been a failure.

## 5. Conclusions

The results of this retrospective series show that conservative surgery retains all its value as long as the indications are carefully selected. This surgery can only be considered after clear and fair information has been provided. The risks of failure must be exposed as well as the possibility of ectopic pregnancy. At this price, the selected patients can benefit from this surgery which allows to obtain several pregnancies in a natural way and at a much lower cost than in vitro fertilization. It would therefore be highly desirable to promote again this surgery which represents a complementary alternative to in vitro fertilization.

## Conflict of interest

The authors declare that they have no conflict of interest.

## References

1. Strandell A, Lindhard A, Waldenstrom U, et al. Hydrosalpinx and IVF outcome: a prospective randomized multicentre trial in Scandinavia on salpingectomy prior to IVF. *Hum Reprod.* 1999;14(11), 2762-9. [PubMed] [Google Scholar].
2. Dechaud H, Daures JP, Arnal F, et al. Salpingectomy before undergoing IVF can increase implantation rates in severe tubal infertility patients: a prospective randomised study. *Human Reproduction Abstracts of 13th Annual Meeting of the ESHRE.* 1997;12:23-4.
3. Lilford RJ, Watson AJ. Has in-vitro fertilization made salpingostomy obsolete? *Br J Obstet Gynaecol.* 1990;97(7):557-560. <https://doi.org/10.1111/j.1471-0528.1990.tb02540.x>.
4. Puttemans PJ, De Bruyne F, Heylen SM. A decade of salpingoscopy. *Eur J Obstet Gynecol Reprod Biol.* 1998;81(2):197-206. [https://doi.org/10.1016/s0301-2115\(98\)00191-2](https://doi.org/10.1016/s0301-2115(98)00191-2).
5. Brosens I, Boeckx W, Delattin P, et al. Salpingoscopy: a new pre-operative diagnostic tool in tubal infertility. *Br J Obstet Gynaecol.* 1987;94(8):768-773. <https://doi.org/10.1111/j.1471-0528.1987.tb03724.x>.
6. Ponomarev VV, Zhuyko AA, Artyushkov VV, et al. Our experience in laparoscopic treatment of tubo-peritoneal infertility. *Gynecol Surg.* 2009;6:5149-50 ([Google Scholar]).
7. Chua SJ, Akande VA, Mol BW. Surgery for tubal infertility. *Cochrane Database Syst Rev.* 2017;1(1):CD006415. <https://doi.org/10.1002/14651858.CD006415.pub3>. Published 2017 Jan 23.
8. Winston RM. The future of microsurgery in infertility. *Clin Obstet Gynaecol.* 1978; 5(3):607-622.
9. Gomel V, Koninckx PR. Microsurgical principles and postoperative adhesions: lessons from the past. *Fertil Steril.* 2016;106(5):1025-1031. <https://doi.org/10.1016/j.fertnstert.2016.08.040>.
10. Trew G, Pistofigdis G, Pados G, et al. Gynaecological endoscopic evaluation of 4% icodextrin solution: a European, multicentre, double-blind, randomized study of the efficacy and safety in the reduction of de novo adhesions after laparoscopic gynaecological surgery. *Hum Reprod.* 2011;26(8):2015-2027. <https://doi.org/10.1093/humrep/der135>.
11. Brown CB, Luciano AA, Martin D, et al. Adept (icodextrin 4% solution) reduces adhesions after laparoscopic surgery for adhesiolysis: a double-blind, randomized, controlled study. *Fertil Steril.* 2007;88(5):1413-1426. <https://doi.org/10.1016/j.fertnstert.2006.12.084>.
12. Chu J, Harb HM, Gallos ID, et al. Salpingostomy in the treatment of hydrosalpinx: a systematic review and meta-analysis. *Hum Reprod.* 2015;30(8):1882-1895. <https://doi.org/10.1093/humrep/dev135>.
13. Yu X, Cai H, Zheng X, et al. Tubal restorative surgery for hydrosalpinges in women due to in vitro fertilization. *Arch Gynecol Obstet.* 2018;297(5):1169-1173. <https://doi.org/10.1007/s00404-018-4695-7>.
14. Chanellas O, Ducarme G, Sifer C, et al. Hydrosalpinx and infertility: what about conservative surgical management? *Eur J Obstet Gynecol Reprod Biol.* 2011;159(1): 122-126. <https://doi.org/10.1016/j.ejogrb.2011.07.004>.
15. Singhal V, Li TC, Cooke ID. An analysis of factors influencing the outcome of 232 consecutive tubal microsurgery cases. *Br J Obstet Gynaecol.* 1991;98(7):628-636. <https://doi.org/10.1111/j.1471-0528.1991.tb13447.x>.
17. Watrelot A, Chauvin G. Current practice in tubal surgery and adhesion management: a review. *Reprod Biomed Online.* 2011;23(1):53-62. <https://doi.org/10.1016/j.rbmo.2011.03.018>.